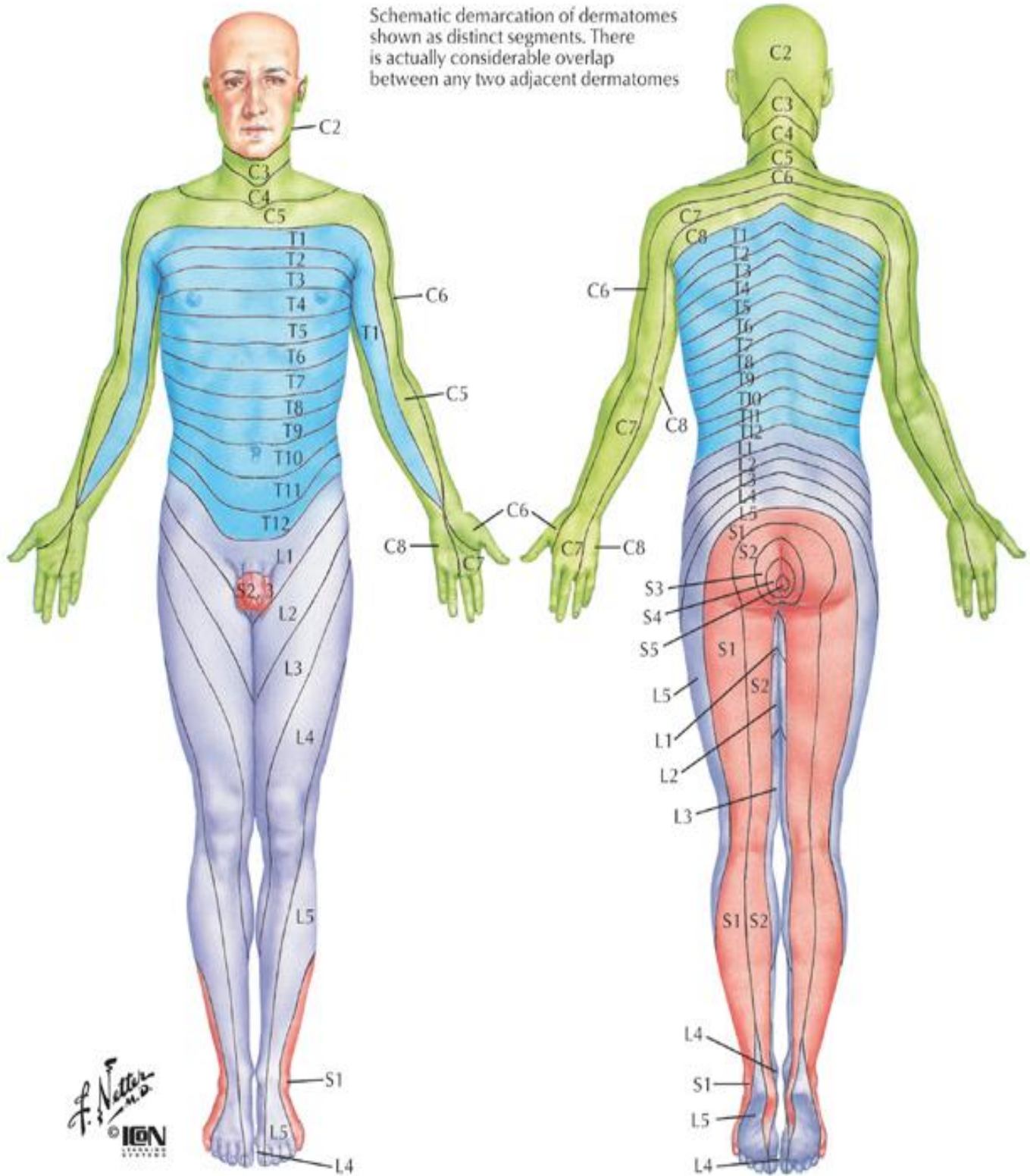


Schematic demarcation of dermatomes shown as distinct segments. There is actually considerable overlap between any two adjacent dermatomes



F. J. Netter M.D.
© IGCN

Levels of principal dermatomes

- C5** Clavicles
- C5, 6, 7** Lateral parts of upper limbs
- C8, T1** Medial sides of upper limbs
- C6** Thumb
- C6, 7, 8** Hand
- C8** Ring and little fingers
- T4** Level of nipples

- T10** Level of umbilicus
- T12** Inguinal or groin regions
- L1, 2, 3, 4** Anterior and inner surfaces of lower limbs
- L4, 5, S1** Foot
- L4** Medial side of great toe
- S1, 2, L5** Posterior and outer surfaces of lower limbs
- S1** Lateral margin of foot and little toe
- S2, 3, 4** Perineum